



Failed VAX-D Treatment of L4-5 Disc Protrusion and Lumbar Scoliosis Treated Successfully with Cox® Technic

submitted March 31, 2010

**Robert P. Rice, D.C., M.S.
Certified Cox® Technic Physician
Amelia Chiropractic Clinic
Fernandina Beach, FL**

This case was unique and presented a challenge due to multiple lumbar disc protrusions, multiple levels of lumbar facet joint degeneration, and lumbar scoliosis with a convexity to the left at L2.

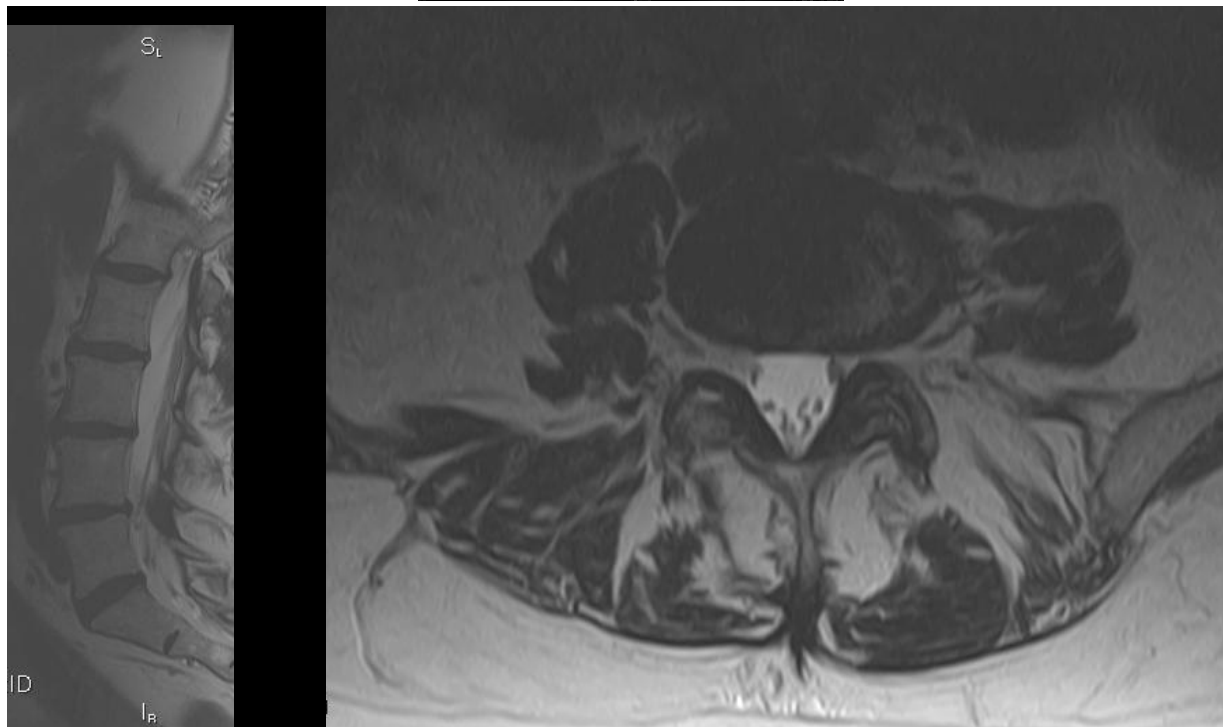
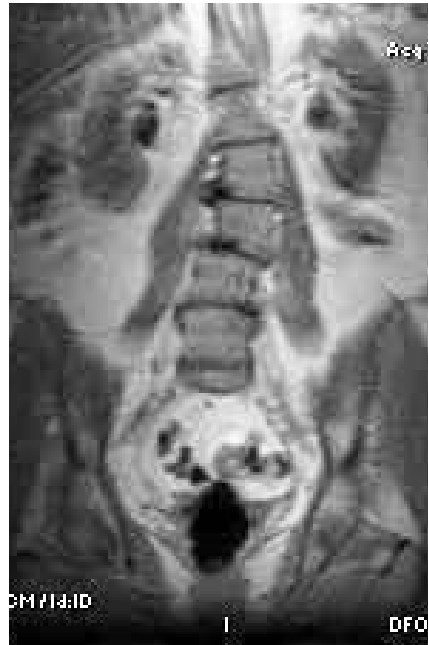Background: The patient is a 59 year-old Caucasian female, who is an insulin dependant diabetic, presents with the chief complaint of bilateral low back pain which started one year previously following a rear end motor vehicle accident.

Previous Care: The patient had tried a course of spinal decompression (VAX-D) and exercise therapy for one year, with little benefit. A follow-up MRI of the lumbar spine one year post VAX-D therapy began revealed a L4-L5 disc protrusion with left foraminal stenosis.

History/Chief Complaint: Bilateral low back pain. She denies radicular or bowel and bladder symptoms and states everything aggravates her low back. Her pain is only slightly relieved by laying flat on her back. She describes her pain as pinching, sharp, stabbing and shooting with motion. Her pain has progressively been getting worse. She states it feels as though her sacrum is bruised and her low back feels heavy. She is afraid to move quickly, and places her hands on her lap to assist in getting up out of a chair or out of the car.

Examination: Pt presents with right antalgia. Examination reveals a positive Minor sign. Bechterew's and straight leg raise were found normal bilateral. Initial low back VAS score was 8 and her pain was increased with sitting. Proprioception, vibration and sensation were found intact bilaterally in the lower extremities, except for the L4-5 left dermatome, which produced decreased sensation on the left at the origin of the tibialis anterior muscle. Heel to toe walk was performed without difficulty bilaterally. Deep tendon reflexes: L4 & S1 were found 2/5 bilaterally. Muscle testing: L1-S1 was found to be 5/5 bilaterally. No pathologic reflexes were elicited. Active range of motion testing of the lumbar spine produced pain and decreased motion in all motions. Palpation revealed pain bilaterally from L1-L4, with increased pain at L4-L5 on the left. It is noted that the patient presents with right antalgia, which is away from the pain at this level. This is consistent with the left lateral disc protrusion. Pain and muscle spasm were also found on the left PSIS.

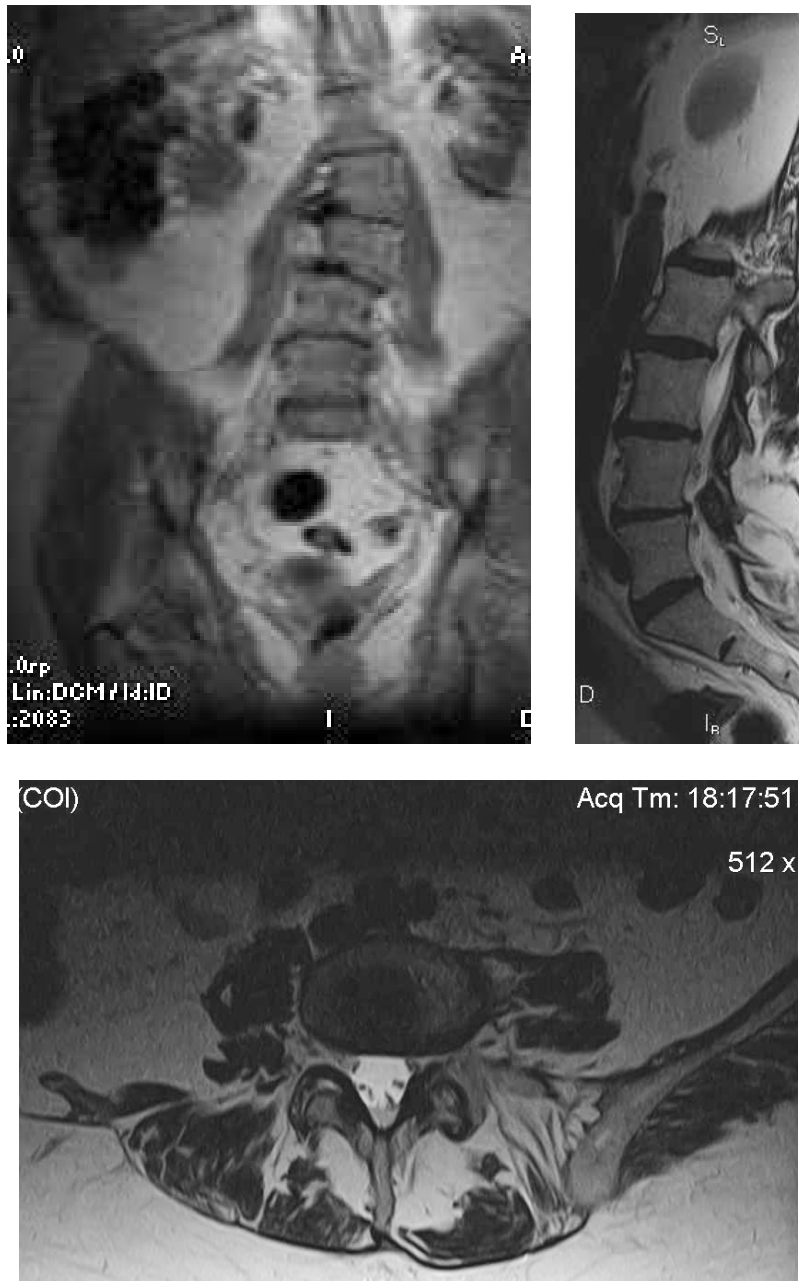
Pre VAX-D Imaging Findings: MRI 5/8/09: L1-2 small right medial disc protrusion without nerve root impingement or displacement. L2-3 through L5-S1 revealed mild circumferential disc herniations with associated osteophytes and no nerve root impingement or displacement. Mild lumbar scoliosis with convexity to the left was noted. Diffuse degenerative disc changes from L2-S1 and anterior spurring of L2-3, L4-5 were found.



May 2009

Due to long standing pain without relief, a second MRI was ordered of the patient's lumbar spine. It should be noted that the second lumbar MRI was performed at the

same facility and the same MRI scanner as the first MRI study. MRI post one year of VAX-D decompression: MRI 3/1/10: Unchanged L1-2 right medial disc protrusion without significant stenosis. Unchanged bulges of the intervertebral discs at the L2-3 and L5-S1 levels were noted. At L4-5, a mid left neural foraminal stenosis was noted. Lumbar scoliosis and spondylosis were also noted.



March 2010

Diagnosis: L1-2 right medial disc protrusion, L2-3 disc protrusion encroaching the ventral aspect of the thecal sac, L3-4, facet joint degeneration, with a disc protrusion encroaching the ventral aspect of the thecal sac, L4-5 facet joint degeneration with a left neural foraminal disc protrusion, L5-S1 facet joint degeneration with a disc protrusion and scoliosis of the lumbar spine.

Treatment: This patient stated she was getting worse and was desperate to try another treatment protocol. She called our office for a consultation and agreed to begin treating on the Cox® instrument. This patient's best relief of her pain was obtained laying flat on her back. The patient understood our goal was 50% relief of her pain in one month, and that we are trying to control, not cure her low back pain. The patient was reminded that a disc can take up to three months to heal. Following tolerance testing, flexion distraction decompression of the L1-2 and L4-L5 disc spaces were instituted initially with protocol I. The instrument was placed in slight caudal flexion to reduce muscle guarding. Interferential current and moist heat was applied to the L1-L5 discs. Our goal is to treat above the disc protrusions. Cox® exercises 1-3 were started on the first day of care to help induce spinal stabilization. Prolonged sitting, bending and lifting were discouraged. Due to the patient's sulphur allergy and past adverse reactions to glucosamine and chondroitin, these supplements were not advised. Fish oil complex, vitamin D3, and boswellia were advised to help rebuild the intervertebral discs and decrease inflammation.

On the third visit, protocol II was initiated with right lateral flexion at L1-2 and L4-L5. Following this treatment the patient stated she did feel decreased low back pain. On the fourth visit protocol II with right lateral flexion was continued. Acupressure was applied to bladder points 24-34, before and after therapy for 15 seconds. Auto Long Y axis traction was initiated and Kinesio tape was applied over the L4-5 disc to help reduce muscle spasms. On the fifth visit, Minor's sign and antalgia were not evident and the patient's VAS had dropped from the original 8 down to a 5. The patient was treated three times a week for three weeks with a result of reduction of pain from a VAS of 8, to a VAS of 5.

The patient has attained 50% relief of pain in twelve visits, and four weeks of care. She states she has noticed a decreased sensation of heaviness in her low back and has also noticed that she can stand for longer periods of time with decreased low back pain.

Discussion: This case study is presented to demonstrate the benefits of Cox® Technic vs. unattended spinal decompression (VAX-D). In this patient, MRI studies revealed multiple levels of disc protrusions with a new finding of left foraminal stenosis post VAX-D therapy. Of concern and our primary level of treatment, was the L4-5 level disc protrusion encroaching upon the left osteoligamentous canal. This could account for compression of both the L4 and L5 nerve roots and dorsal root ganglion. Considering the L2-3 and L3-4 disc protrusions, our decision was to contact the L2 spinous process to: 1) decompress the discs inferior to this level, and 2) laterally flex the caudal section of the Cox® instrument to allow for the lumbar scoliosis at L2. The ability of the Cox® instrument to accommodate a scoliosis patient and laterally flex the lumbar spine has benefited the management of this patient's condition immensely.

It is of interest to this doctor to discuss the methodology of scleratogenous and discal pain mentioned earlier in this case, review briefly the research involved, and consider their relationships to this case. Scleratogenous pain is described by Cox as pain producing no motor or sensory deficits in the lower extremity. ⁱ Cramer & Darby have found that facet arthrosis may further decrease the space available for the exiting nerve roots and may contribute to radicular pain of discal origin. ⁱⁱ Jeffries shows us that pain

from the facet joints may be difficult to localize because each facet joint capsule receives multiple levels of sensory information from the medial branch of the posterior primary division (dorsal ramus) at its level, and from a medial branch of the dorsal ramus of the level above and below.ⁱⁱⁱ

Conversely, Bogduk has studied disc innervation and he reveals disc compression can produce radicular symptoms (caused by activation of sensory fibers at the level of the dorsal root ganglion) due to the unique innervation of the annulus fibrosis. The outer 1/3 receives both vasomotor (small vessels) and sensory (nociceptive and proprioceptive) fibers. The lateral and anterior portions receive gray rami sympathetic fibers. The posterolateral portion receives both direct branches from the anterior primary division (ventral ramus) and grey rami. The posterior disc receives its innervation from the sinuvertebral nerve (recurrent meningeal nerve).^{iv} In addition, Cramer and Darby have found that because the dorsal root and ventral nerve root are adjacent to each other, compression of the dorsal root is usually accompanied by compression of the ventral root as well. Compression of the ventral root results in motor weakness. Therefore, radicular pain may be accompanied by motor weakness.^v

Although this patient did not suffer from radicular symptoms or motor weakness, it is important to develop a treatment plan based on the exam and clinical findings rather than MRI findings alone. We are reminded that it is not in the patient's best interest to traction below a medial disc (at L1-2, as was done with the VAX-D treatment) as this possibly will pull the herniation onto the corresponding nerve root and increase pain and the symptoms referenced above. Consequently, the decision and ability to treat at the proper levels, as well as, to help to restore physiological motion to the facet joints, was important to this doctor, and especially, the patient.

Respectfully submitted,
Robert P. Rice, D.C., M.S.
Certified Cox® Technic Physician
runningdoctor@hotmail.com

References:

ⁱ Cox, JM: *Low Back Pain, Mechanism, Diagnosis and Treatment*, 6th Edition Philadelphia: Lippincott, Williams and Wilkins 1999 pg 602.

ⁱⁱ Cramer, G. D. and S.A. Darby. *Basic and Clinical Anatomy of the Spine, Spinal Cord, and ANS*. St. Louis: Mosby, 1995. pgs 367.

ⁱⁱⁱ Jeffries, B. (1988). Facet joint injections. *Spine: State of the art reviews*, 2 409-417.

^{iv} Bogduk, N. (1976). The anatomy of the intervertebral disc syndrome, *Med J Aust*, 1, 878-881.

^v Cramer, G. D. and S.A. Darby. *Basic and Clinical Anatomy of the Spine, Spinal Cord, and ANS*. St. Louis: Mosby, 1995. pg 369.

Acknowledgements: I would like to thank Julie Cox-Cid, not only for her help in preparing this case report, but also for all that she does “behind the scene.” Julie, your efforts have not gone unnoticed. Dr. Cox, your contributions to the progress of the chiropractic profession are not only remarkable, but inspiring.